UNIVERSITY OF GOTHENBURG

Monitoring of human uterus transplantation with cervical biopsies - a provisional scoring system for rejection.

Johan Mölne

Department of Pathology and Genetics, Sahlgrenska Academy, University of Gothenburg, Sweden

Disclosures

- None

Introduction

- Absolute uterine factor infertility (AUFI) has until now been the major untreatable form, of female infertility (≈1:10.000).
  - uterine agenesis (Mayer-Rokitansky-Küster-Hauser syndrome)
  - hysterectomy
- Recently uterus transplantation has proven to be the first option for treatment of AUFI, with the demonstration of successful live births.

History of uterus transplantation

- First transplant in Saudi Arabia 2000
  - vascular thrombosis after ≈ 3 months
- Uterus tx from deceased donor in Turkey 2011
  - technical success but no childbirth
- First child born in Gothenburg 2014
  - Brännstrom M. Lancet 2015; 385: 607-616.
  - Utx trial started 1999, small and large animals, primates and finally humans
  - 9 women transplanted, 2 early failures
  - 6 healthy babies born so far

Today

- Several centers have started Utx trials
  - Nov 2015 a living donor in China
  - 2016-17 eleven living donor cases
    - 6 in Dallas, USA
    - 3 in Prague, Czech Republic
    - 1 in Tubingen , Germany
    - 1 in China
  - 2016-17 five deceased donors
    - 3 in Prague, Czech Republic
    - 1 in Cleveland, USA
    - 1 in Sao Paulo Brazil

- No children born yet
- Early failures reported in USA

Immunosuppressive therapy

- Kidney-type regimen used in Gothenburg
- Induction therapy
  - ATG (2,5 mg/kg body weight) and steroids (500 mg Solu-Medrol) day 0 and day 1
- Maintenance therapy
  - mycophenolate mofetil (MMF) and tacrolimus for six to eight months
  - thereafter tacrolimus monotherapy - if possible

Immunosuppression - protocol

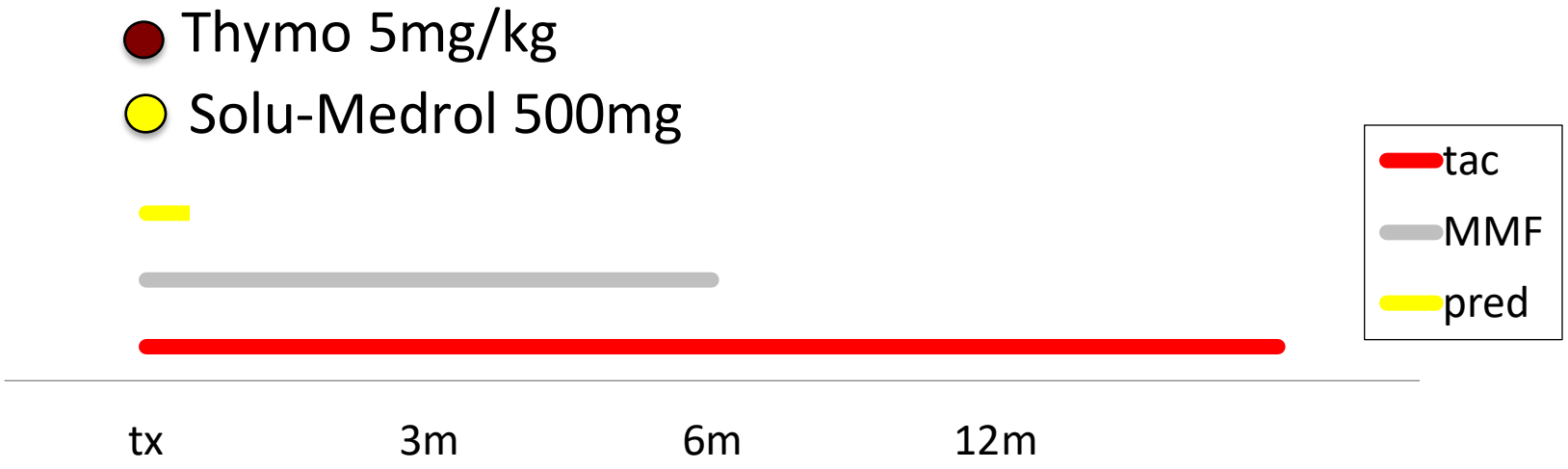

Biopsies

- Cervical punch biopsies were used
  - needle biopsies for endometrium/myometrium on 2 occasions
- Protocol schedule
  - 1, 2 and 4 weeks
  - thereafter monthly for at least a year
  - after one year, 1-3 month intervals

Histology

- Biopsies were fixed in formalin for > 2h under constant shaking, embedded in paraffin, sectioned and stained with H&E

- Immunoperoxidase was used in selected cases
  - CD3, CD56, CD20, CD68 (C3c, C5b-9) all from Dako
  - C4d (ab 58781; Abcam, Cambridge, UK)

Grading of rejection

- Adopted schedule from a baboon Utx trial
  - Johannesson et al. Hum Reprod 2013; 28: 189-198
- The schedule was revised (at 36 months post transplantation) and a borderline category added
  - Mölne J. et al. Am J Transplant. 2016 Nov 21. doi: 10.1111/ajt.14135. Epub ahead of print)

Normal cervical biopsy

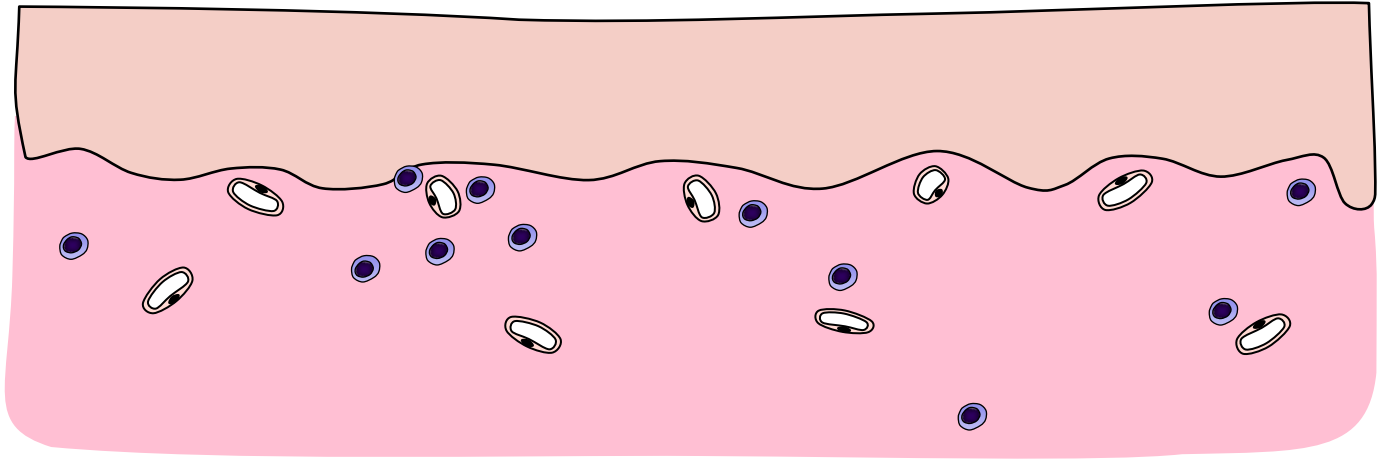

Borderline changes

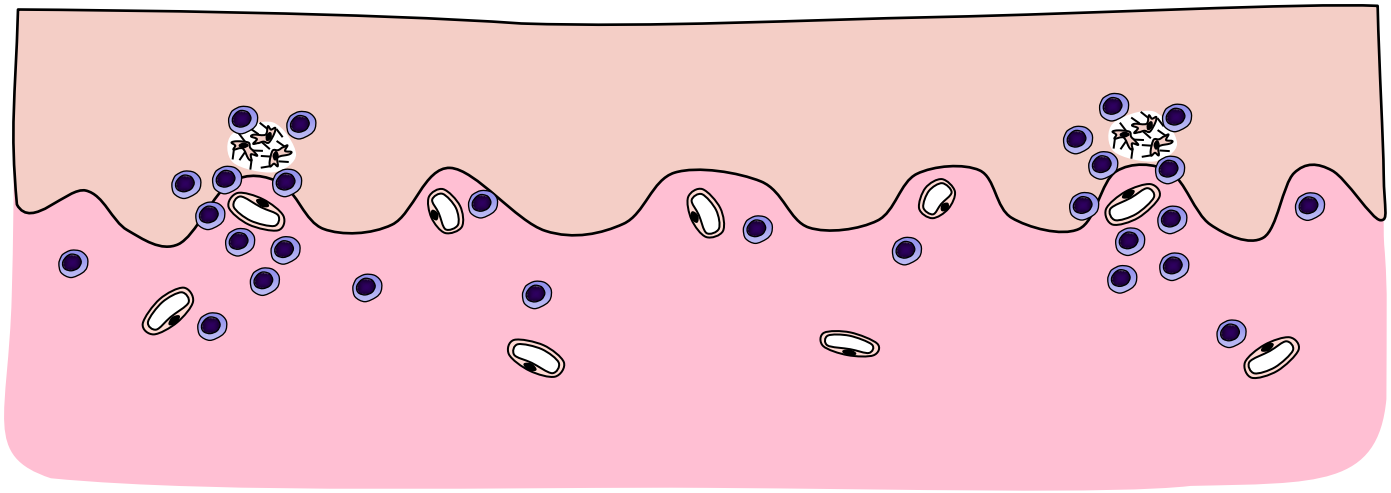

Grade 1 rejection

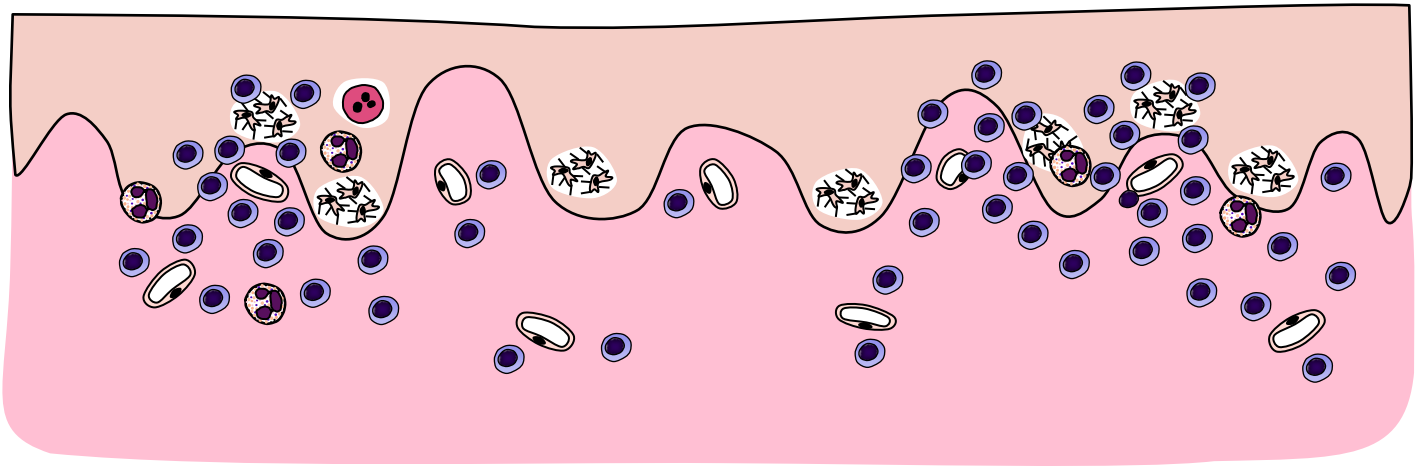

Grade 2 rejection

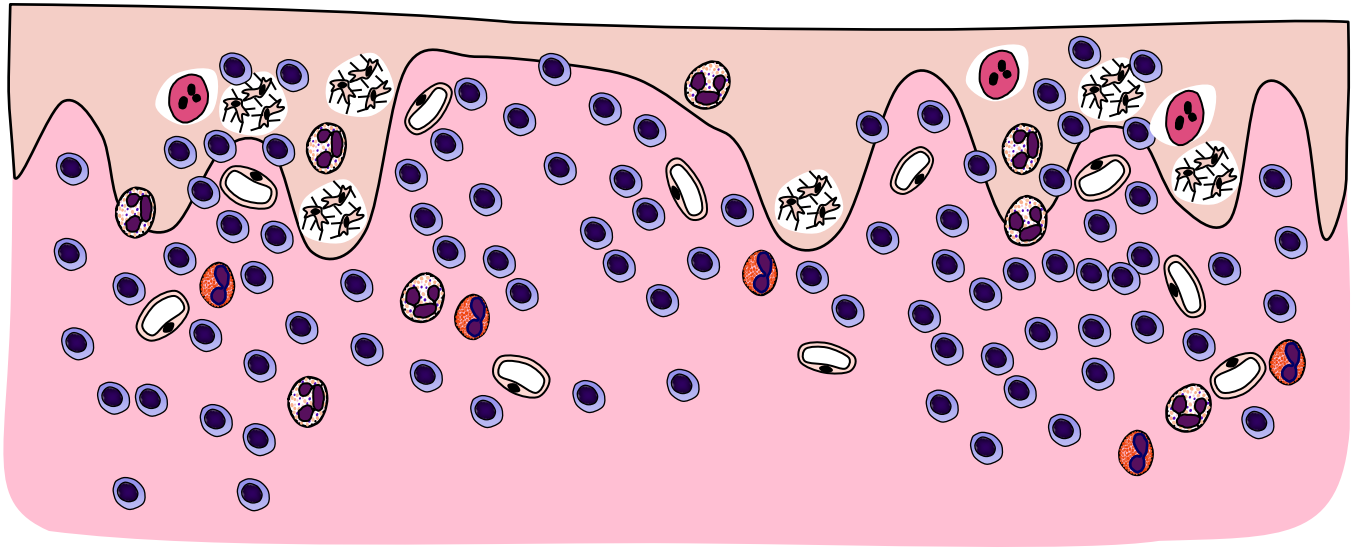

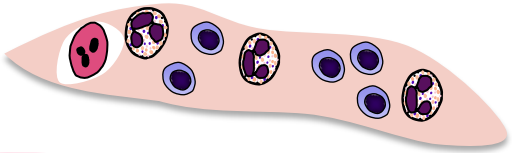

Grade 3 rejection

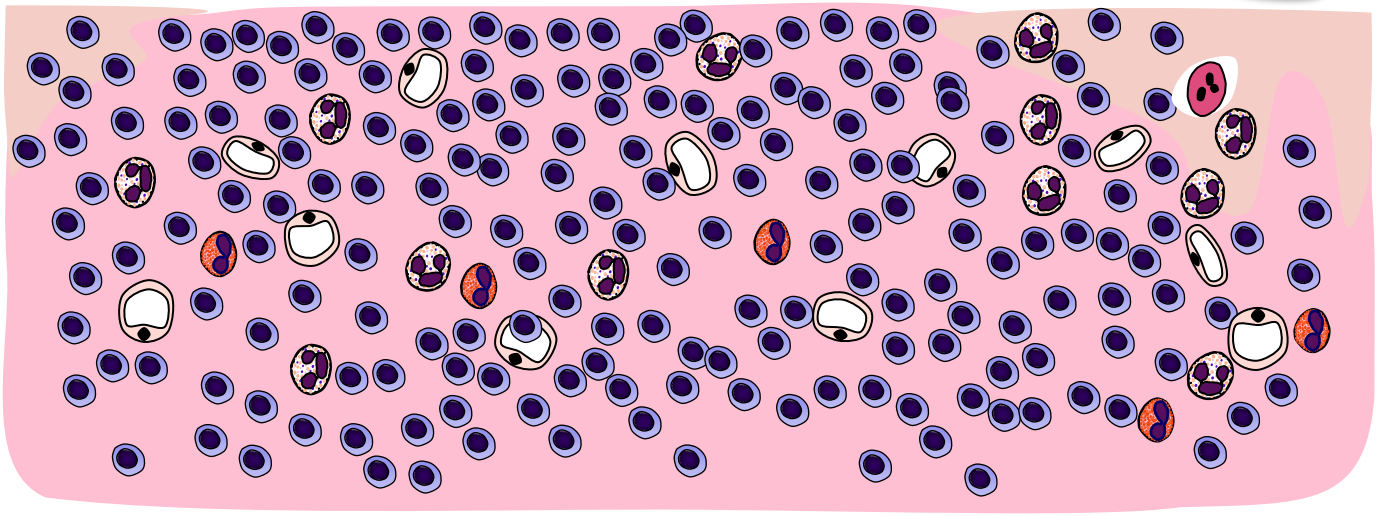

- **Borderline changes**

  At least two, small, nested foci of interface inflammation in the basal epithelial cell layers, dominated by lymphocytes.

  Focal intercellular edema.

  Minimal stromal inflammation, particularly in the papillary stroma.

- **Grade 1 rejection**

  Mild mixed inflammatory cell infiltrate in the basal epidermal layer, dominated by lymphocytes.

  Single epithelial apoptotic bodies.

  Low-grade stromal inflammation and edema.

Grade 2 rejection

Moderate inflammatory cell infiltrate with intraepidermal influx (exocytosis), dominated by lymphocytes and with some neutrophils.

May show reduced surface epithelial thickness, some epithelial apoptotic bodies.

Marked, mixed stromal inflammation and edema

Grade 3 rejection

Significant diffuse, mixed inflammatory cell infiltrate dominated by lymphocytes and presence of neutrophils and eosinophils.

Apoptotic bodies.

Epithelial erosions/ulcerations, focal to complete.

Focal necrosis can be seen.

Dense and continuous stromal infiltrate (mixed).

Normal biopsy

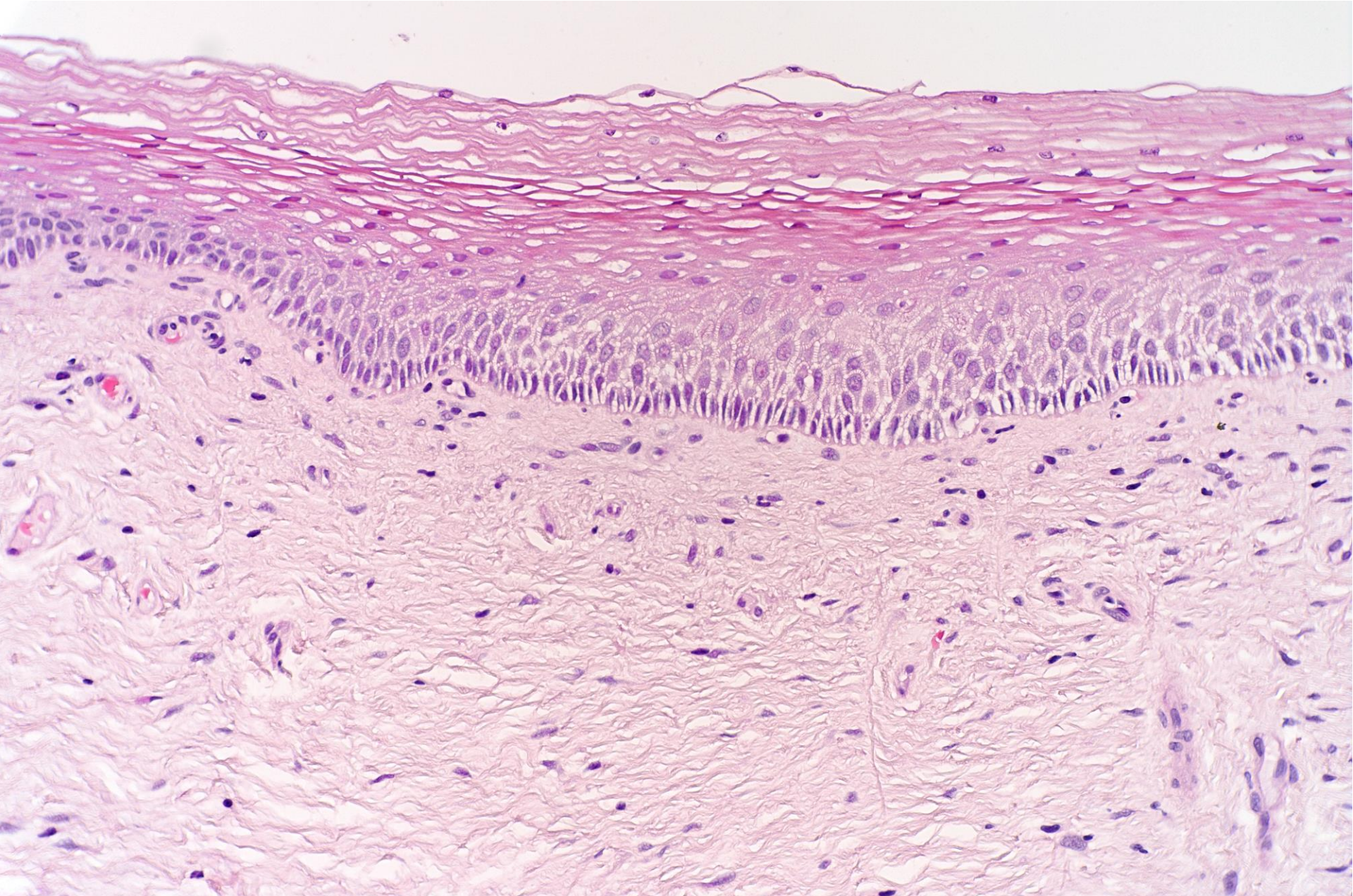

Borderline changes

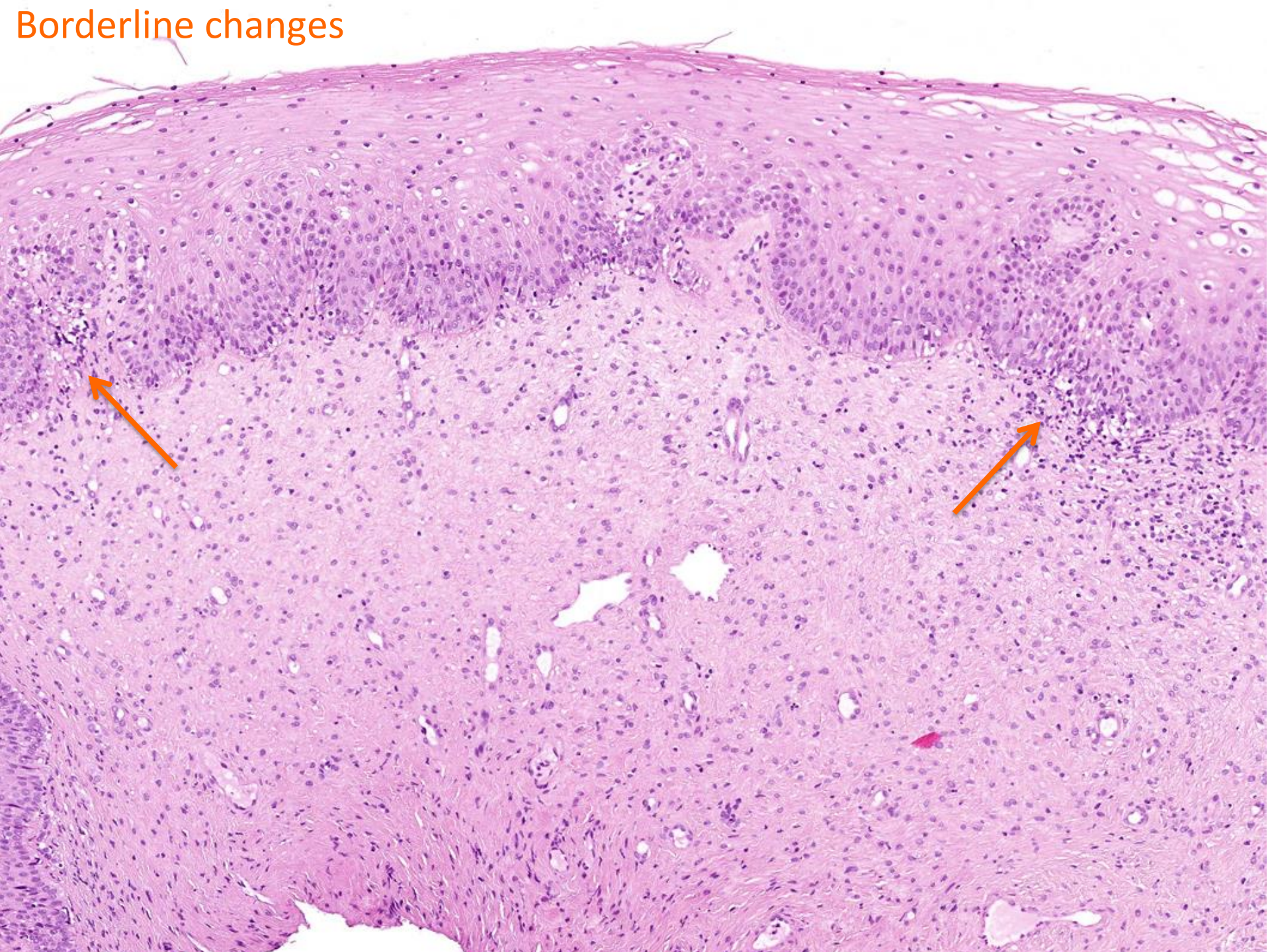

Borderline change CD3

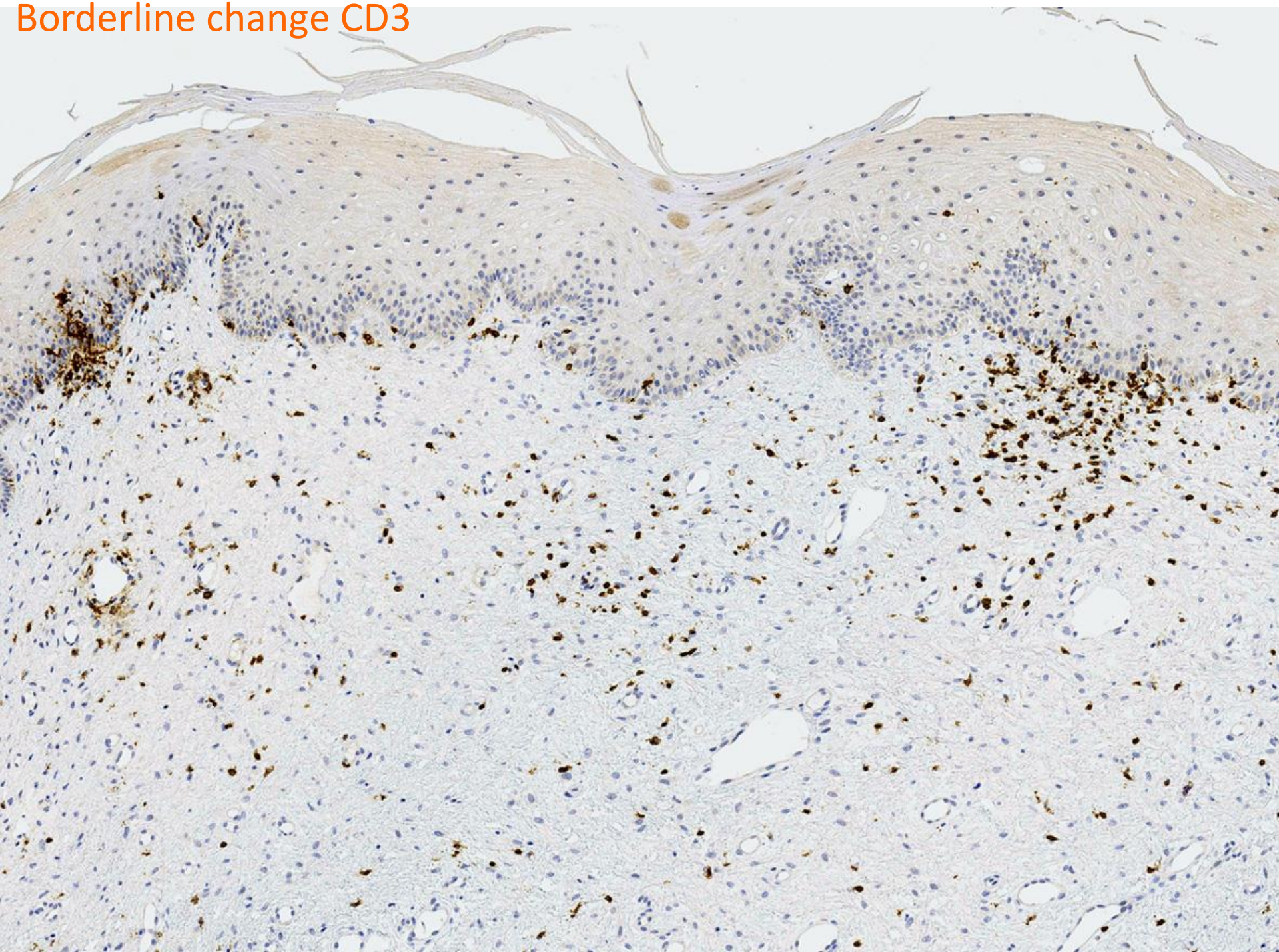

Borderline change CD20

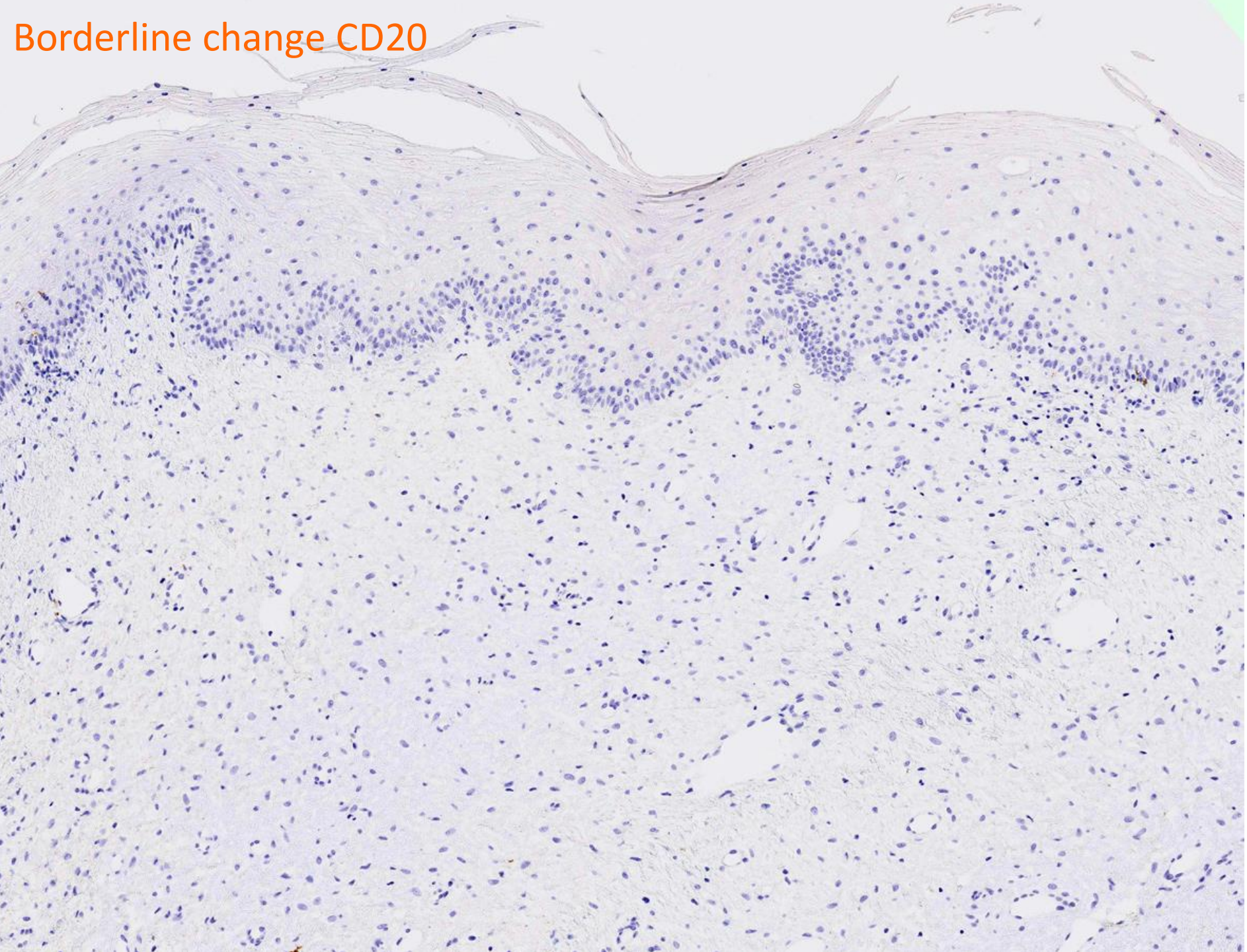

Borderline change CD68

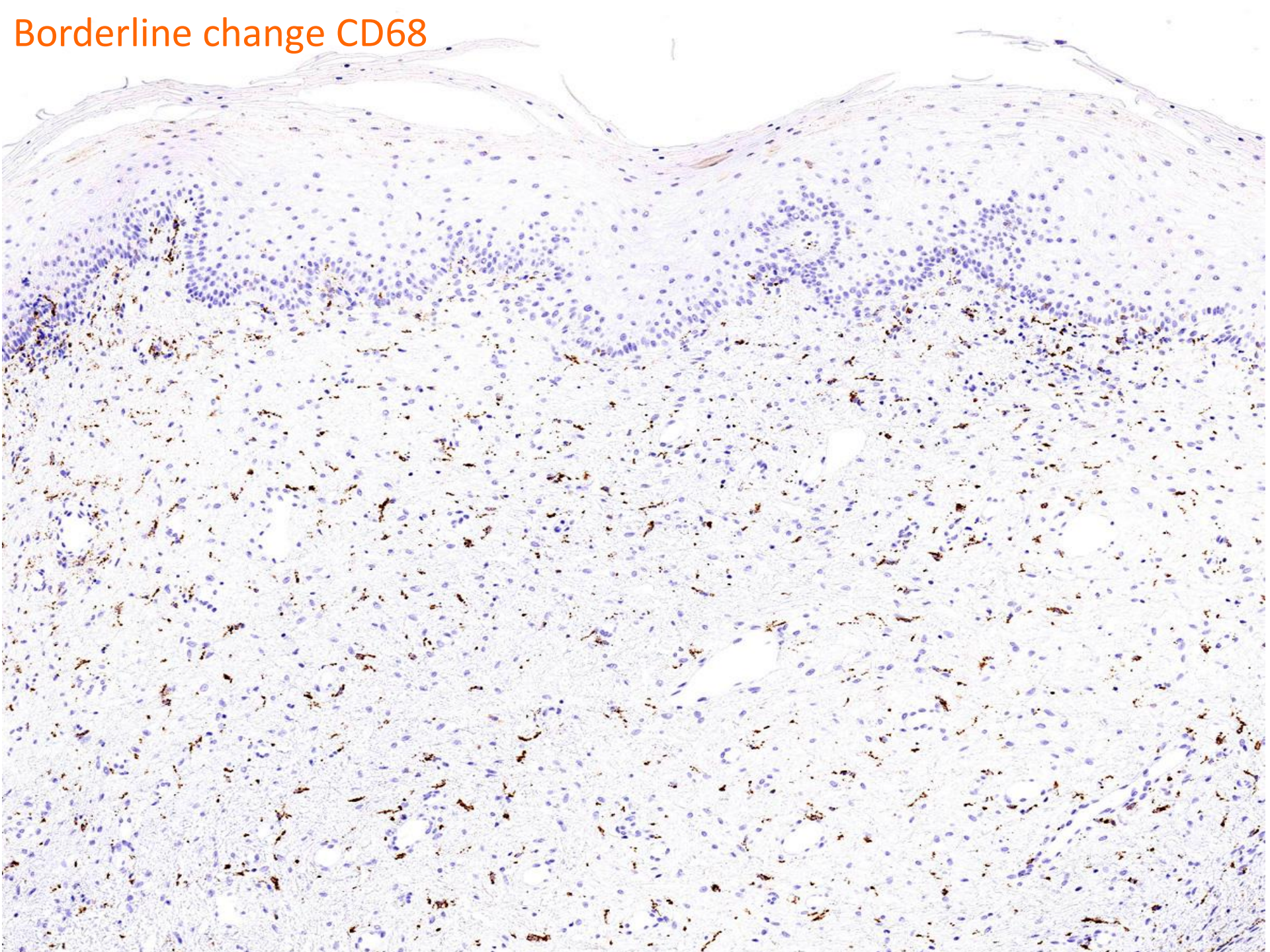

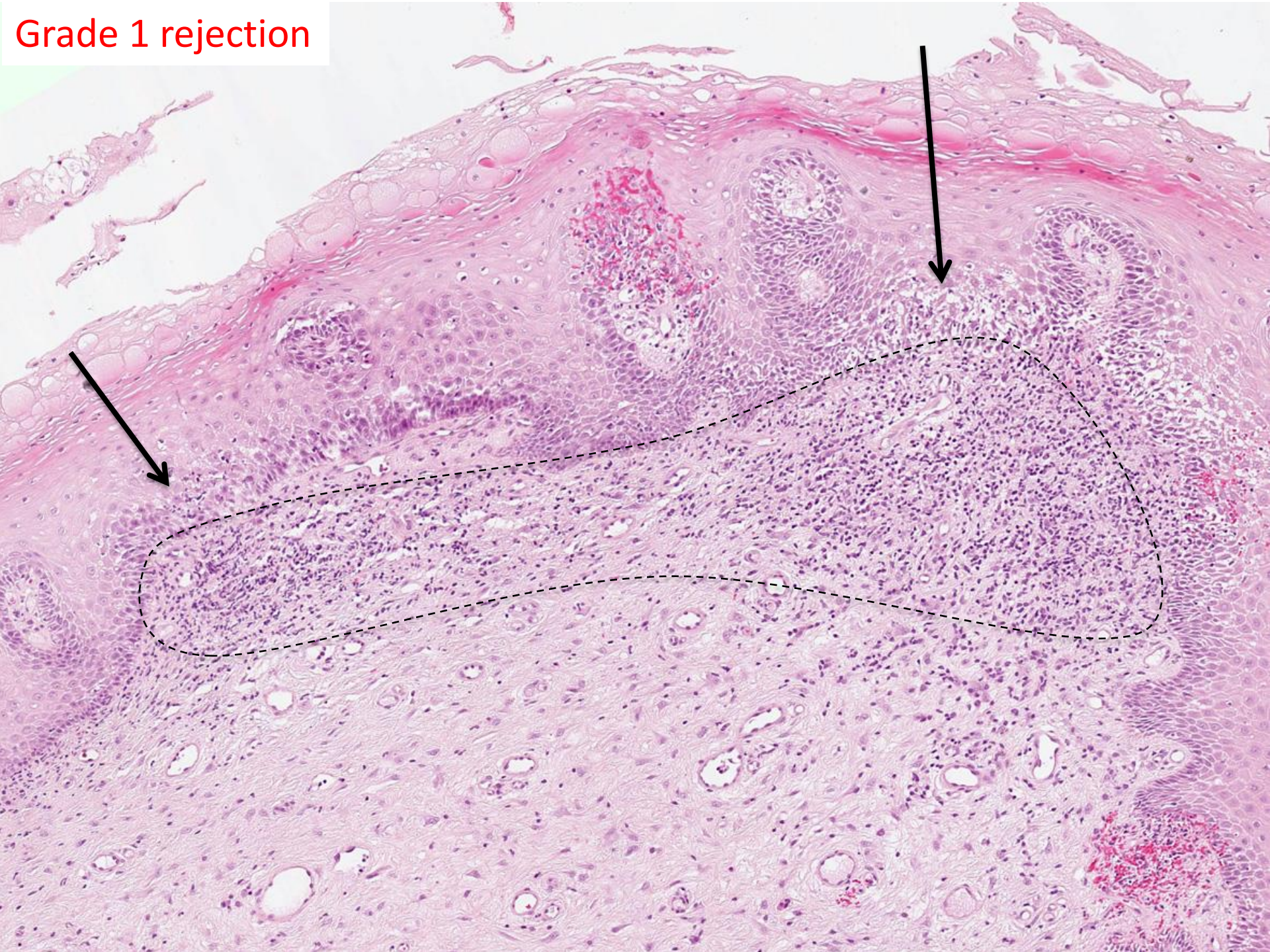
Grade 1 rejection

Grade 1 rejection CD3

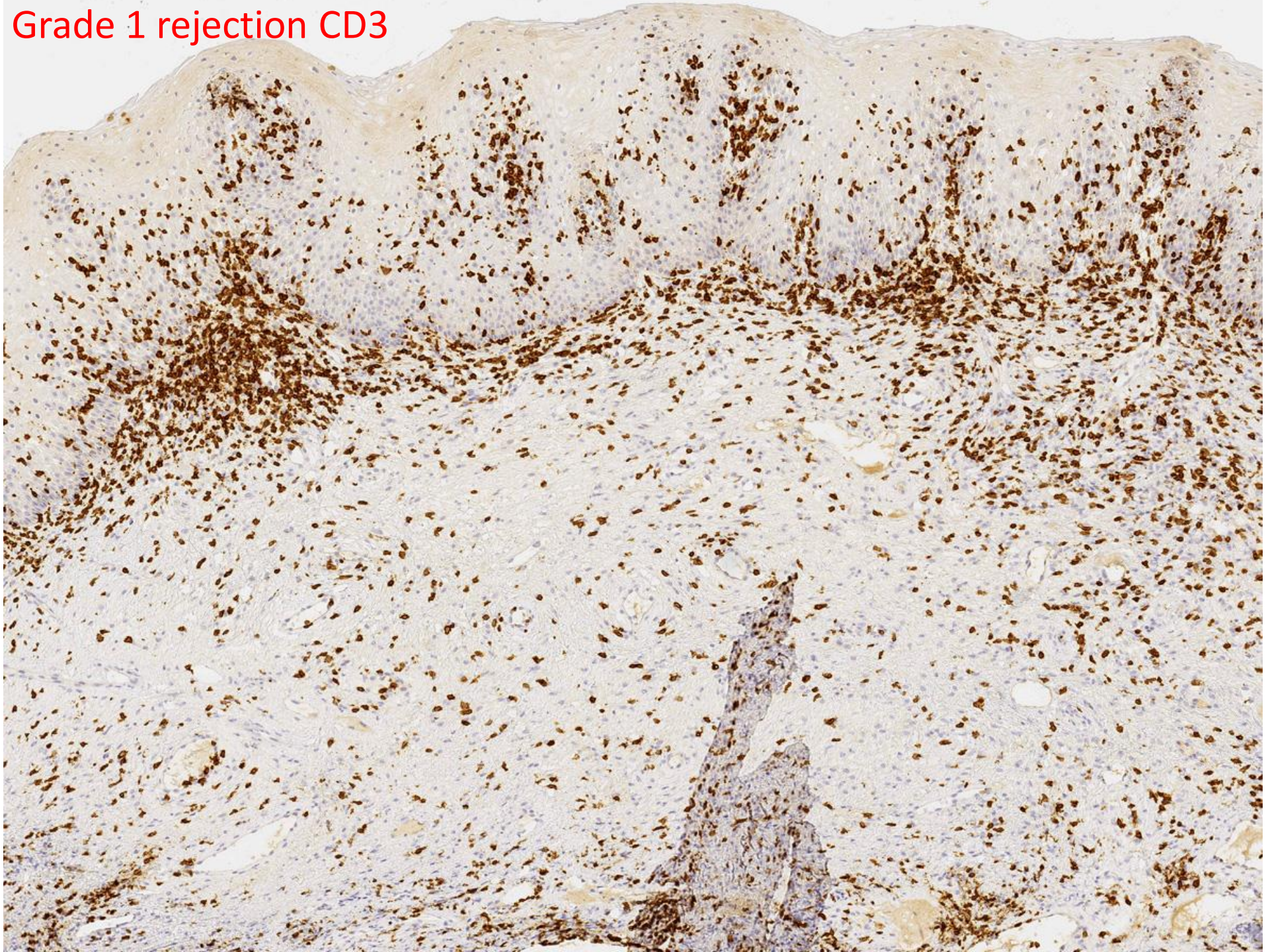

Grade 1 rejection CD20

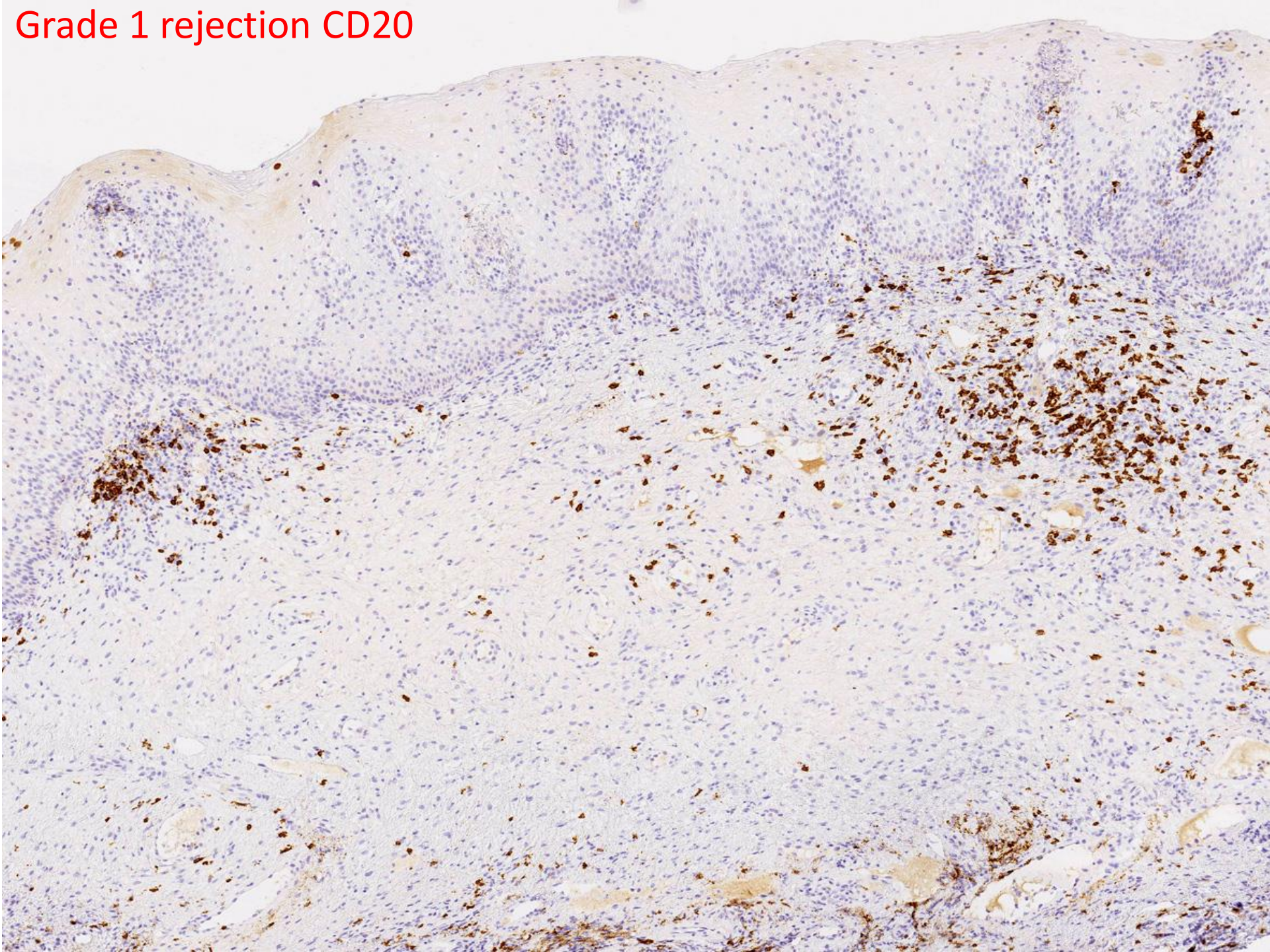

Grade 1 rejection CD68

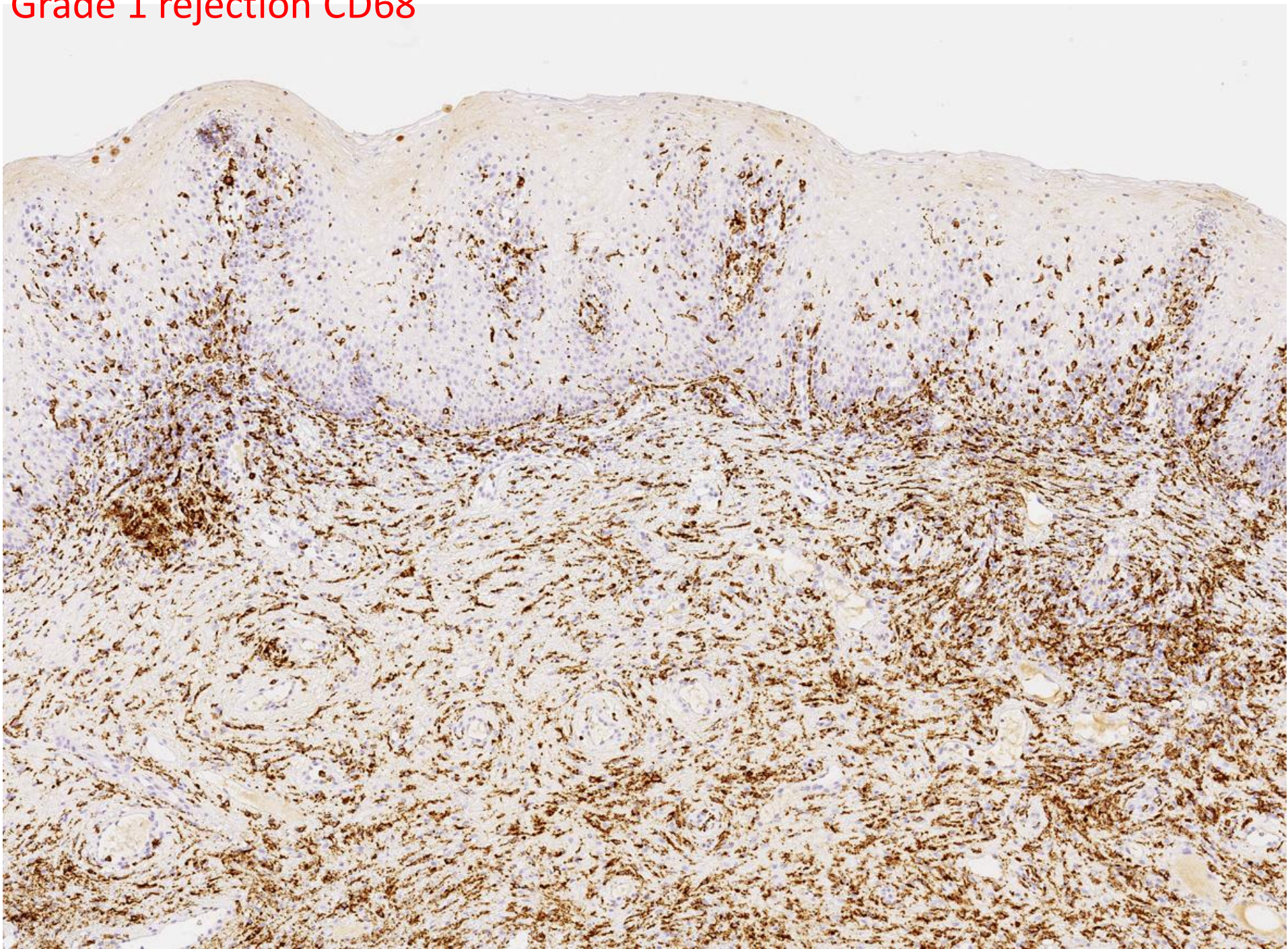

Grade 2 rejection

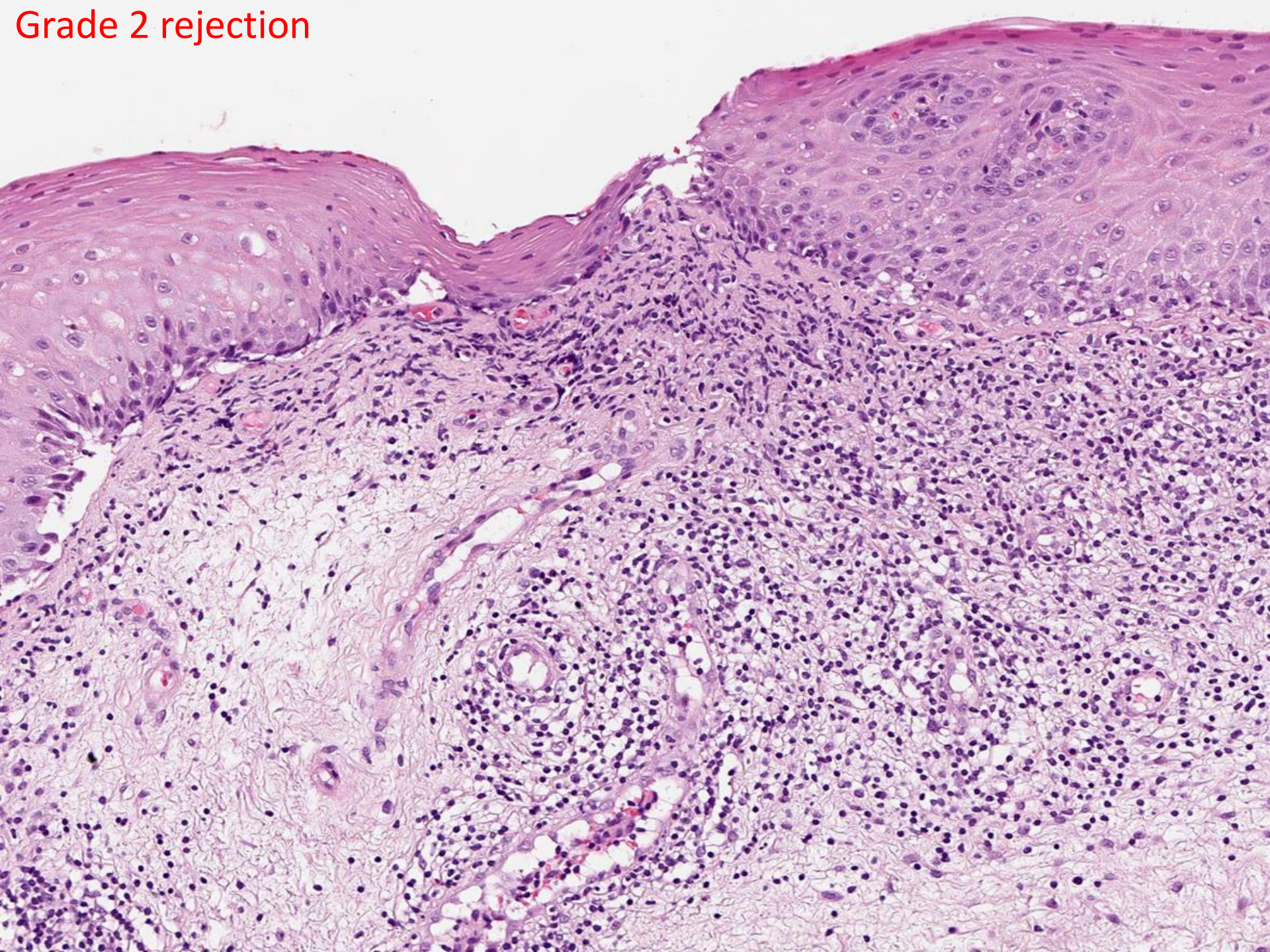

Grade 2 rejection

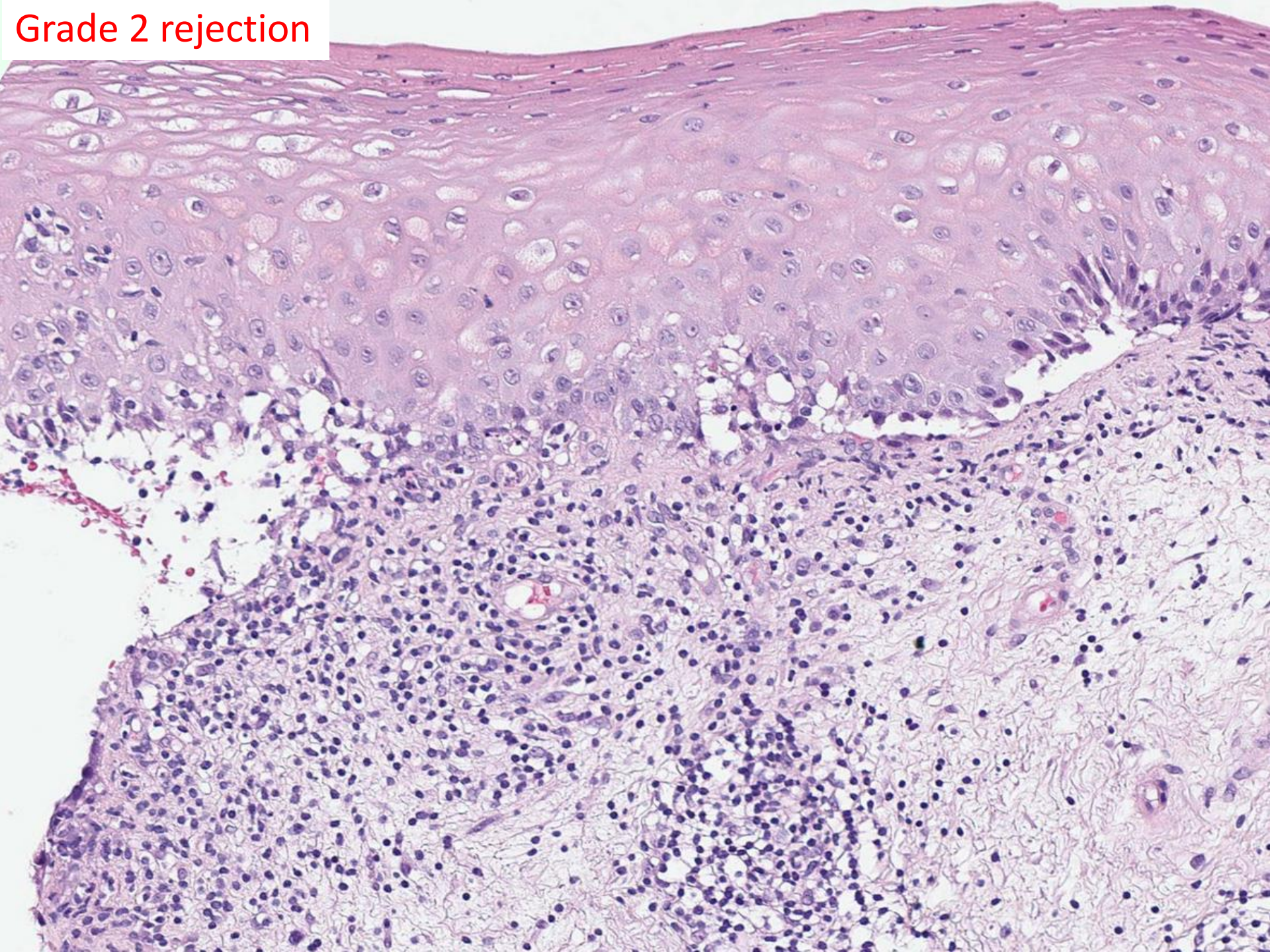

Grade 2 rejection CD3

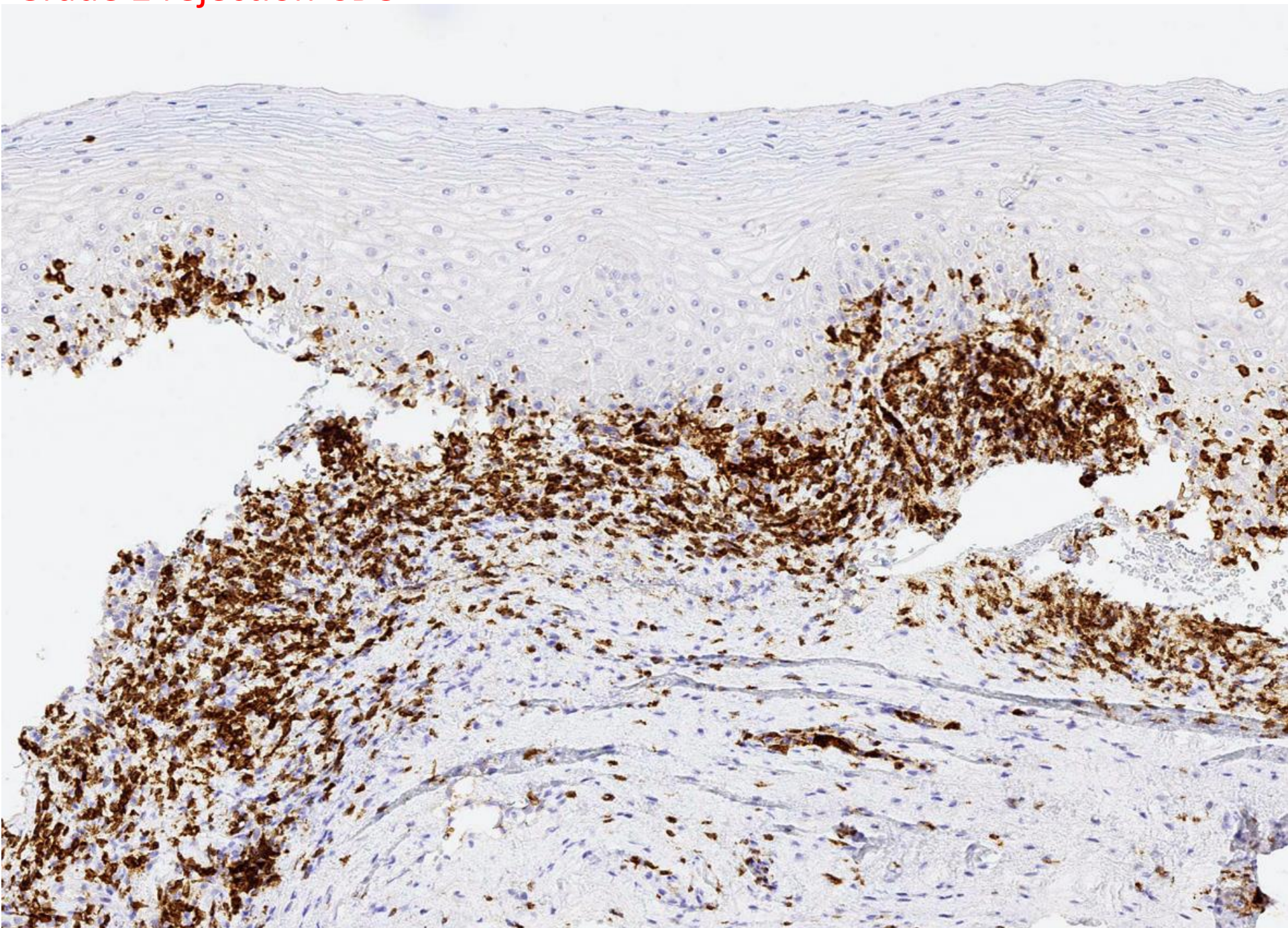

Grade 2 rejection CD20

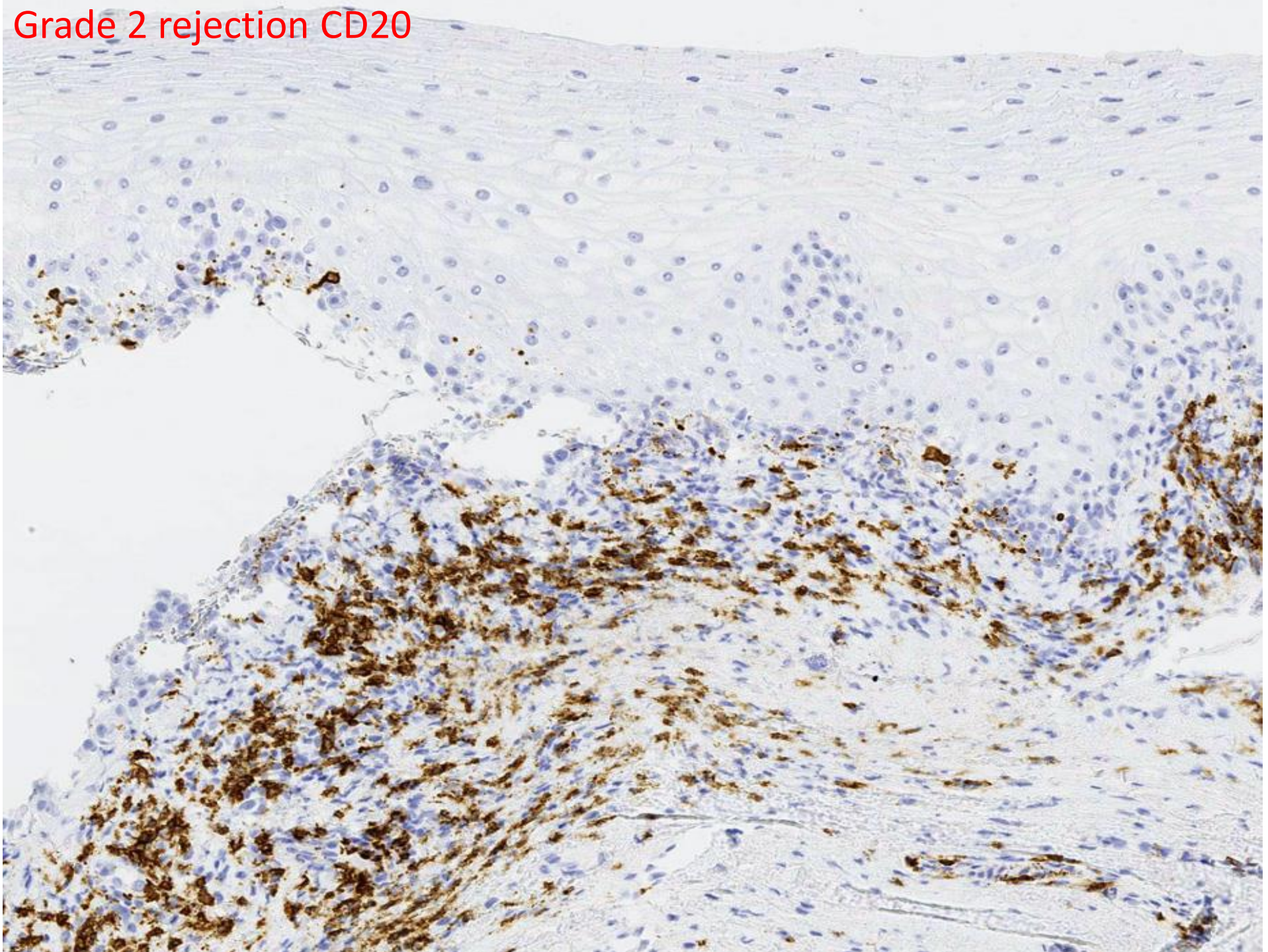

Grade 2 rejection CD68

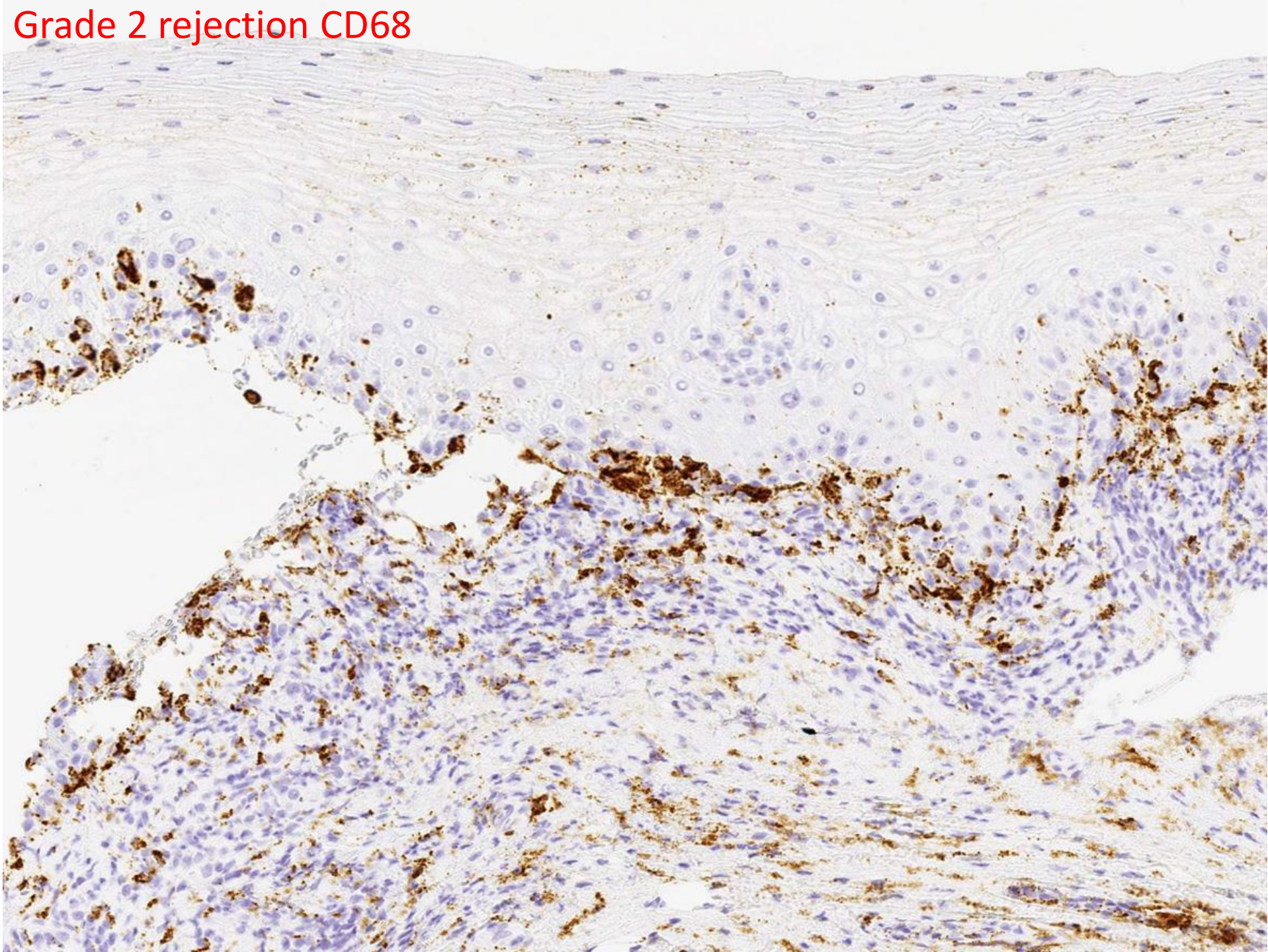

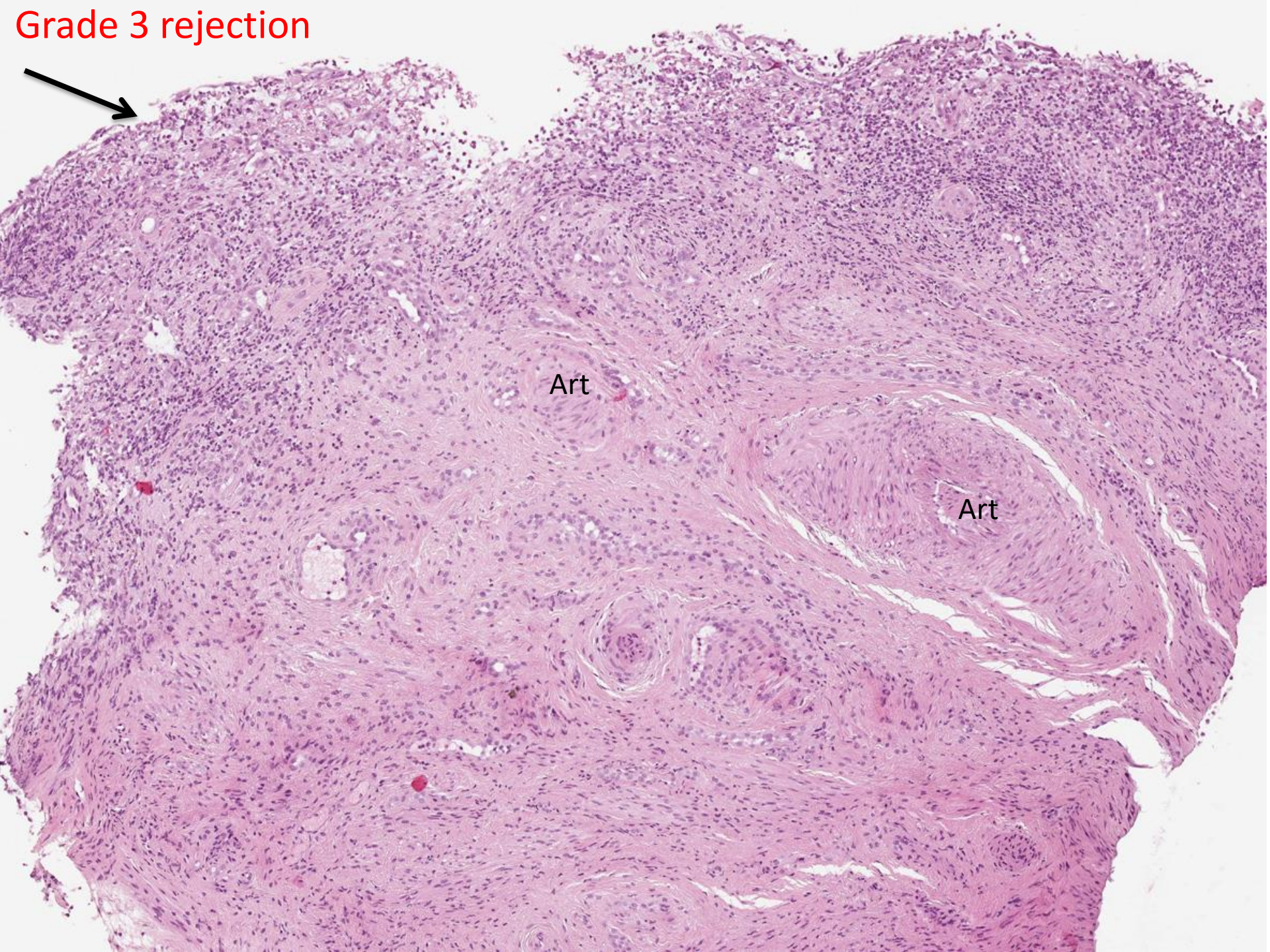
Grade 3 rejection
Art
Art

Grade 3 rejection CD3

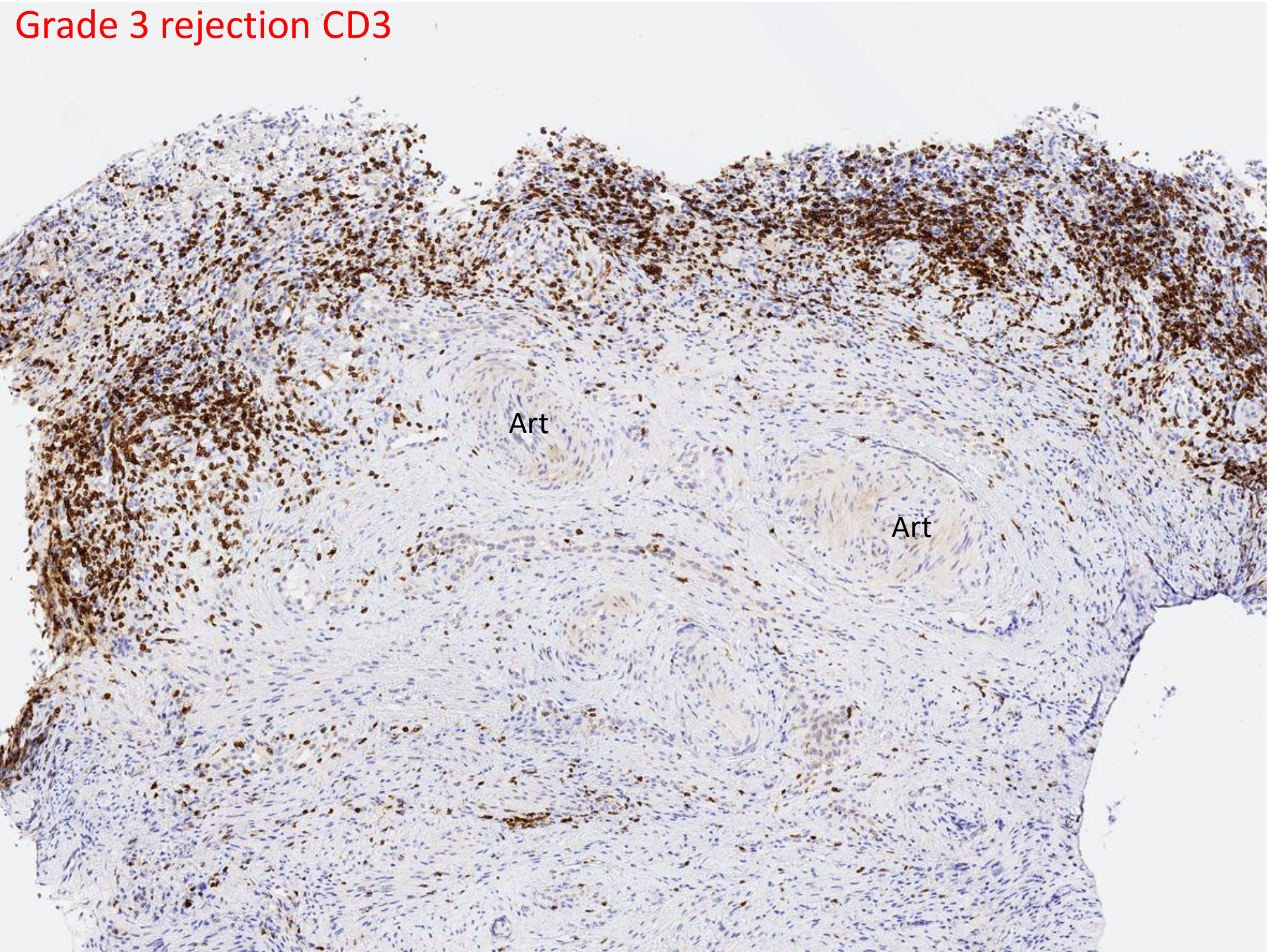

Grade 3 rejection CD20

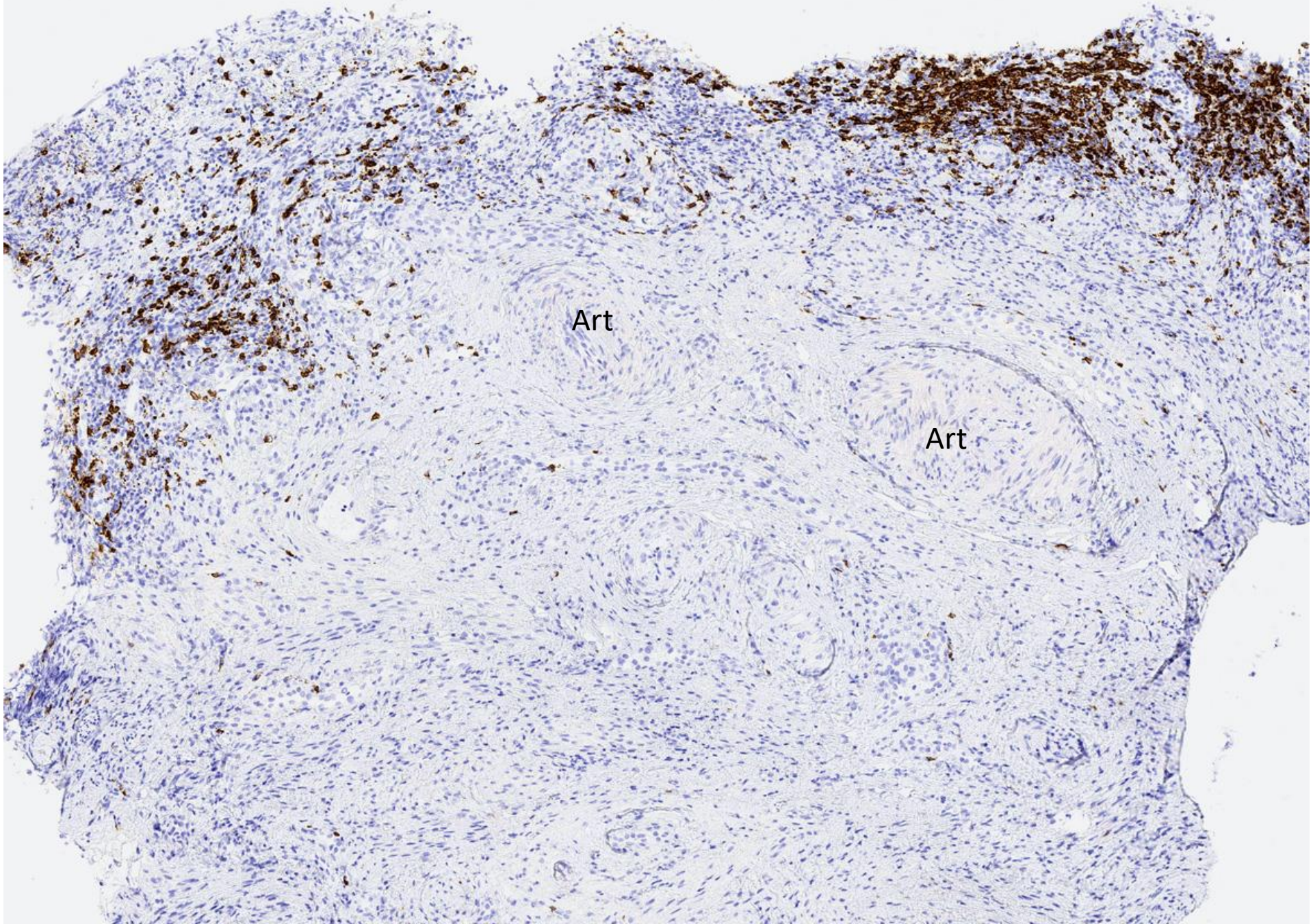

Grade 3 rejection CD68

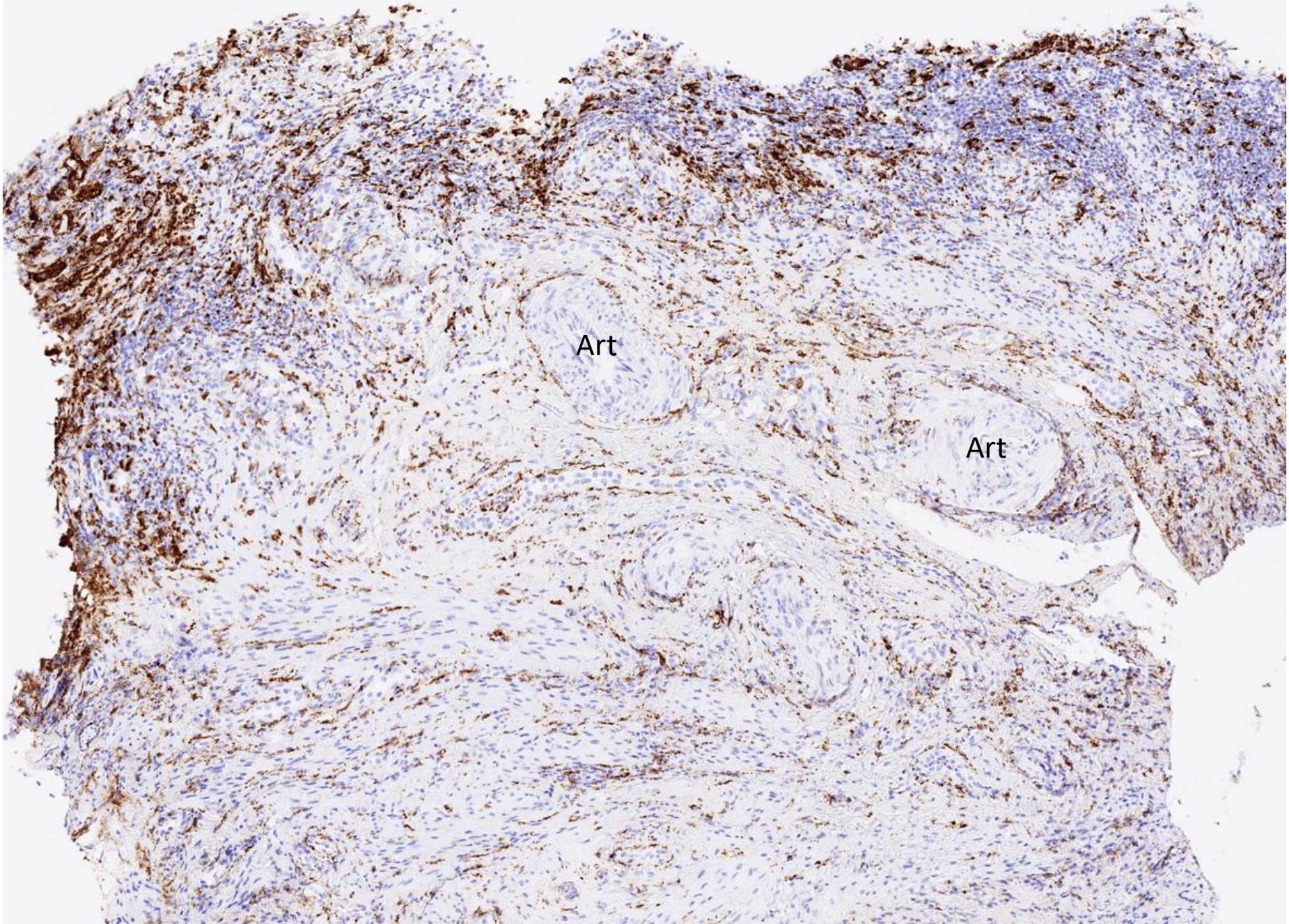

Summary

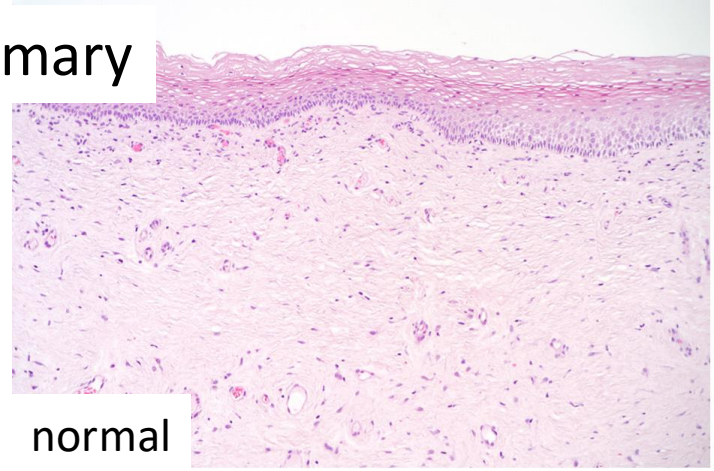
normal

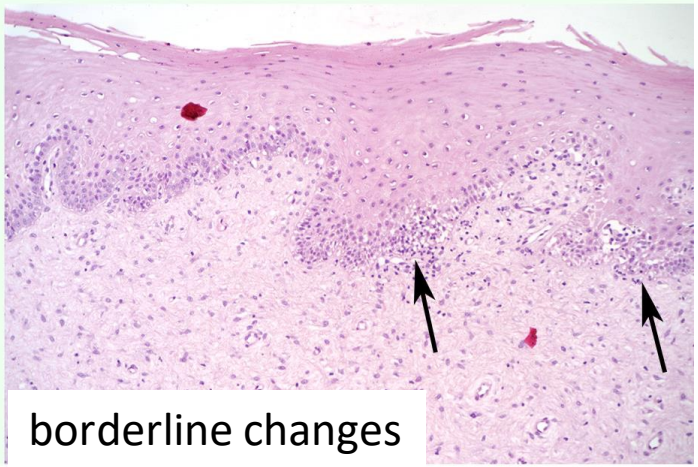
borderline changes

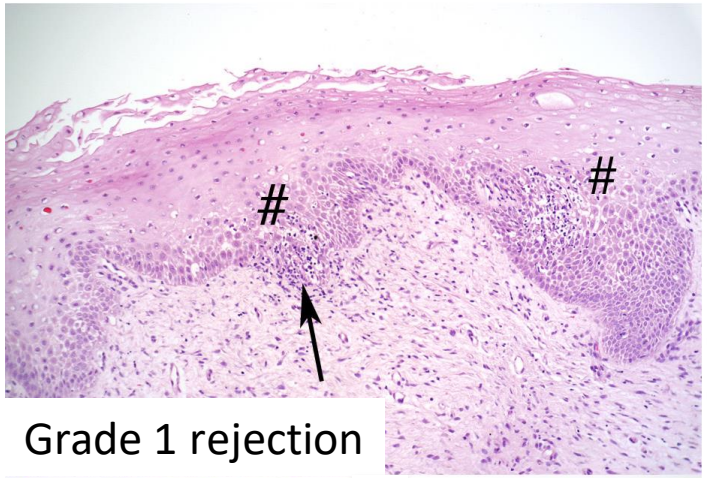
#
#
Grade 1 rejection

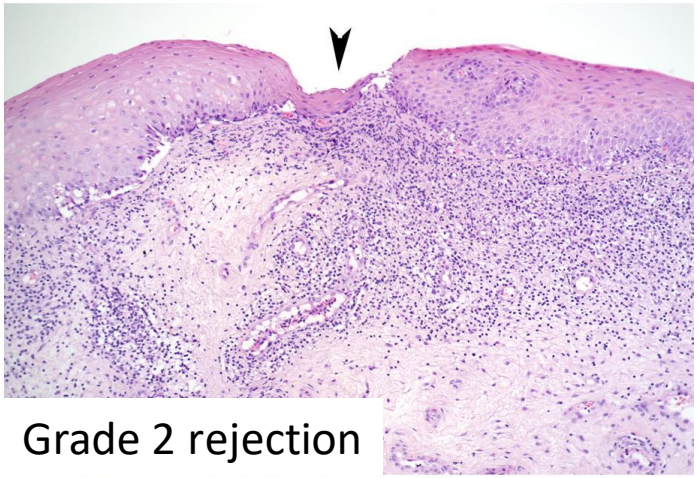
Grade 2 rejection

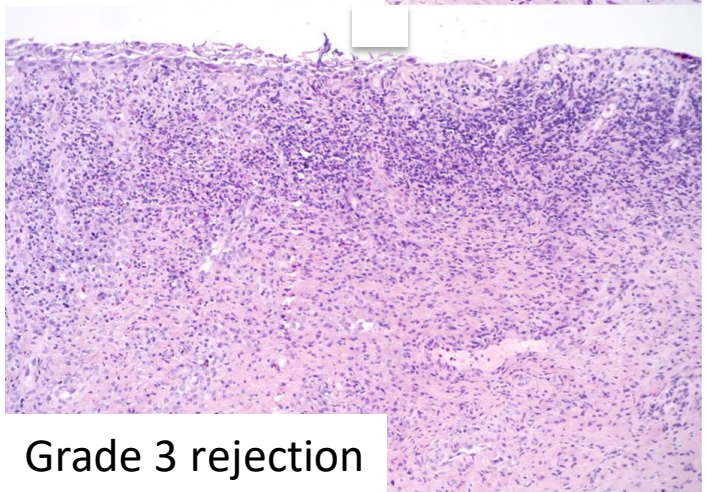
Grade 3 rejection

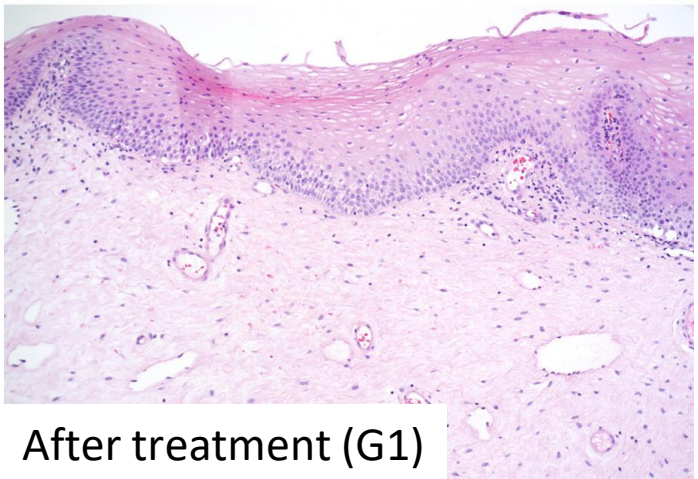
After treatment (G1)

Results

- 163 biopsies were performed within the first 36 months in 7 patients.
- 13 biopsies (8.0%) in five patients showed rejection
- 15 biopsies (9.2%) in five patients were evaluated as borderline changes
- 135 (82.8%) were normal

- Staining for CD3, CD20, and CD68 showed a T-cell dominant inflammation but staining was not considered necessary for routine clinical practice.

- C4d staining was negative in all biopsies investigated and none of the patients had DSA
  - (complement staining was not useful)

Table 4 Maximal immune cell infiltrate.

	CD3	CD20	CD68
Baseline biopsies, n=5	42 (25-50)	0	21 (10-25)
Normal transplant biopsies, n =8	50 (25-100)	6.2 (0-25)	49 (10-100)
Borderline changes, n=11	115 (50-200)	8.8 (0-100)	48 (10-100)
Grade 1 rejection, n=9	122 (50-500)	61 (0-200)	41 (10-100)
Grade 2 and 3 rejection, n=4	425 (200-500)	137 (50-200)	32 (10-100)

Mean values and (range)

Mölne et al AJT (accepted 2016)

UTX Gothenburg - Immunosuppressive treatment, rejections, events

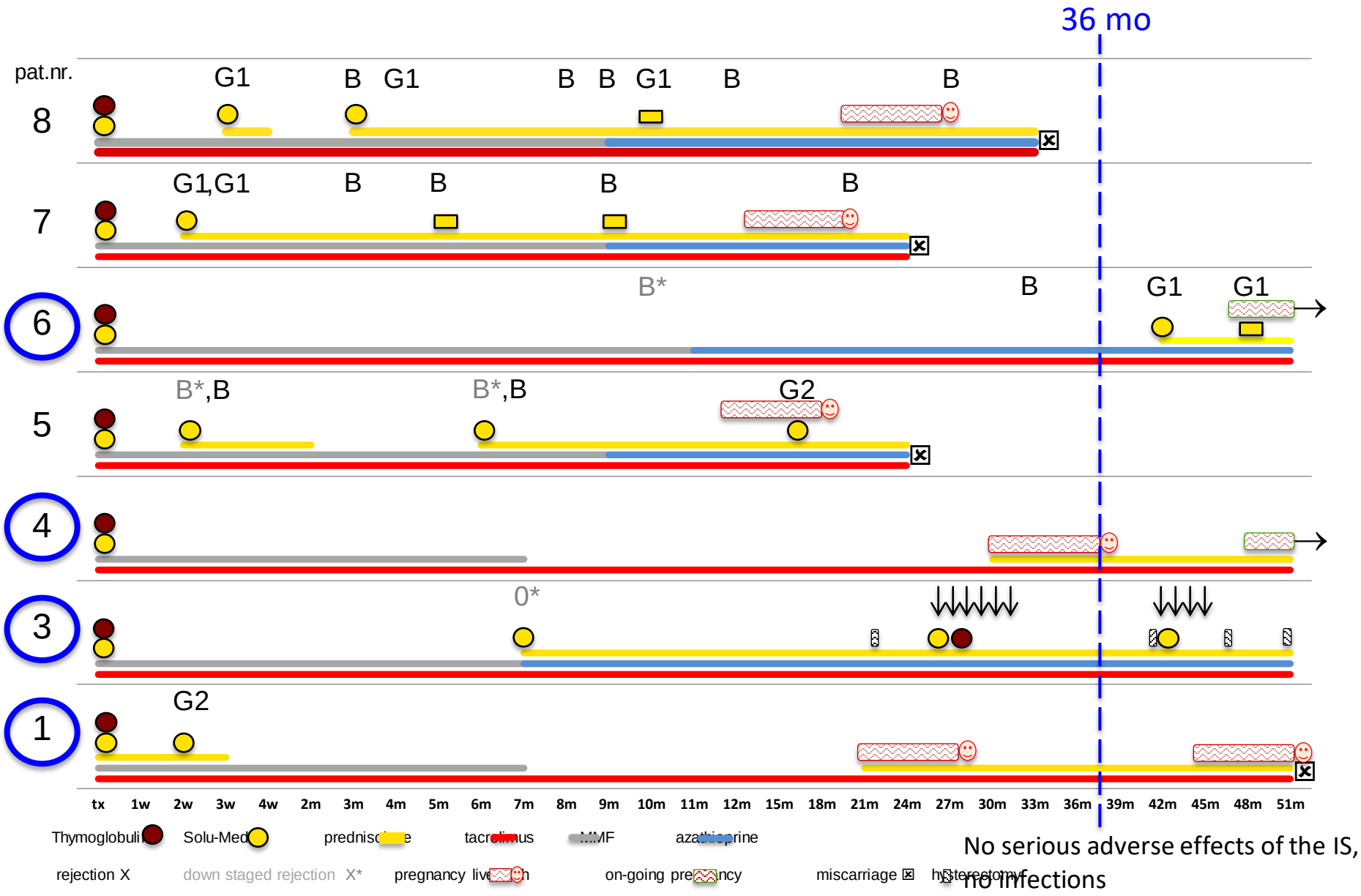

No serious adverse effects of the IS, no infections

Thanks to all coworkers !

- **Mats Brännström** and his large multi diciplinary team!
- Verena Bröcker – Pathology
- Ola Nilsson – Pathology
- Jana Ekberg – Nephrology and transplantation

Banff CTA 2007 classification of skin containing CTAs

- Grade 0

  No or rare inflammatory infiltrates.

- Grade I

  Mild. Mild perivascular infiltration. No involvement of overlaying epidermis.

- Grade II

  Moderate. Moderate-to-severe perivascular inflammation with or without mild epidermal and/or adnexal involvement. No epidermal dyskeratosis or apoptosis.

- Grade III

  Severe. Dense inflammation and epidermal involvement with epithelial apoptosis, dyskeratosis and/or keratinolysis.

- Grade IV

  Necrotizing acute rejection. Frank necrosis of epidermis or other skin structures.

Rejections (first 36 months)

- G1-G3 on 13 biopsies (7 rejection episodes)
- 2 patients had 0 rejections
- 3 patients had 1 rejection
- 1 patient had 2 rejection episodes
- 1 patient had 3 rejections
- 2 early failures (thrombosis, ischemia/infection)

All treated with steroids (S-M / pred)

One rejection - steroid-resistant, treated with Thymoglobulin